

Long-retained Tracheostomy Tube as an Unusual Endobronchial Foreign Body: A Case Report

KOMAL RATHOD¹, AJAY CHAVHAN², PRATAP SINGH PARIHAR³, SARASWATHULA BHARADWAJ⁴



ABSTRACT

Foreign bodies in the tracheobronchial tree are uncommon in adults and typically involve aspirated debris. Retained or neglected tracheostomy tubes as airway foreign bodies are extremely unusual. Imaging is essential for detecting, localising, and assessing problems. Here, we present a 60-year-old female who presented with persistent cough, worsening dyspnoea, and repeated episodes of lower respiratory tract infection over the last few weeks. The patient had past history of tracheostomy approximately 20-25 years ago (exact indication and duration unknown). A radio-opaque tubular structure was visible on a chest radiograph along the right main bronchus. A metallic foreign body, identified as a long-retained tracheostomy tube, was successfully removed after bronchoscopy verified its presence. A normal carina was then restored. This case involves an unusual endobronchial foreign body in an adult. This neglected tracheostomy tube requires a radiological scan, namely X-ray, to detect airway dysfunction and parenchymal changes, thereby averting long-term morbidity.

Keywords: Airway, Bronchoscopy, Carina, Metallic foreign body, Parenchymal changes

CASE REPORT

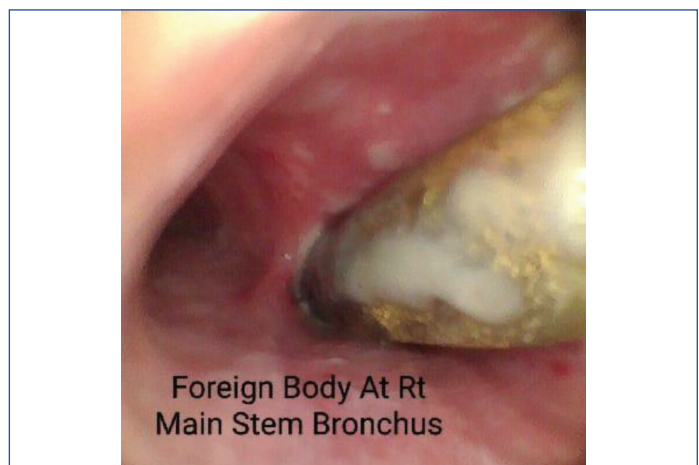
A 60-year-old female presented with persistent cough, worsening dyspnoea, and repeated episodes of lower respiratory tract infection over a period of last few weeks. She also experienced multiple episodes of fever and a productive cough suggestive of recurrent chest infection.

The patient had a past history of tracheostomy approximately 20-25 years ago (exact indication and duration unknown). Since then, there had been no documented follow-up, tube inspection, or tracheostomy care.

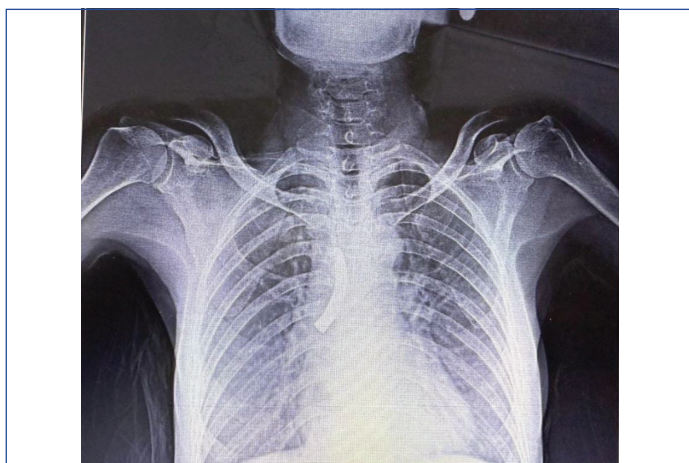
Clinical examination revealed reduced breath sounds over the right hemithorax. Inspiratory crepitations were heard in the right inframammary and infrascapular regions. The patient exhibited no stridor or wheezing. Complete Blood Count (CBC), Erythrocyte Sedimentation Rate (ESR), C-Reactive Protein (CRP), and tests for liver and kidney function were all within normal ranges.

Chest radiograph (PA view) shows a well-defined radio-opaque tubular structure projecting over the right hilar region, coinciding with the expected route of the right major bronchus. Ill-defined patchy opacities in the right lung suggested a post-obstructive infection [Table/Fig-1].

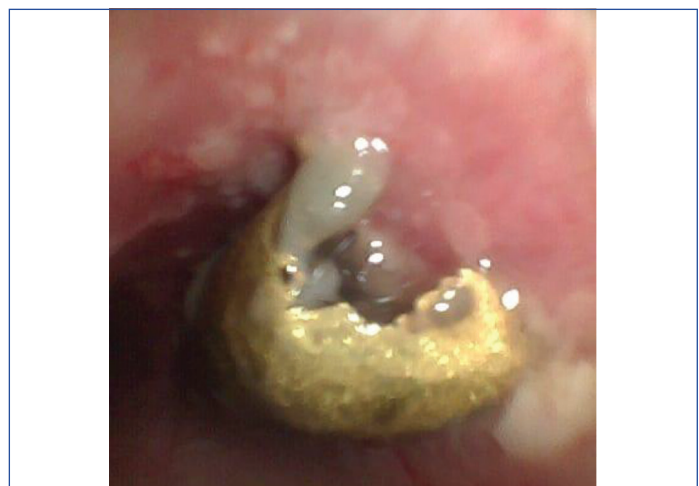A rigid bronchoscopy revealed a metallic tubular foreign body in the right main bronchus, partially occluding the lumen [Table/Fig-2]. The surrounding mucosa showed erythema, congestion, and granulation tissue, indicating chronic irritation [Table/Fig-3].



[Table/Fig-2]: Bronchoscopic view of fractured tracheostomy at the right main stem bronchus.

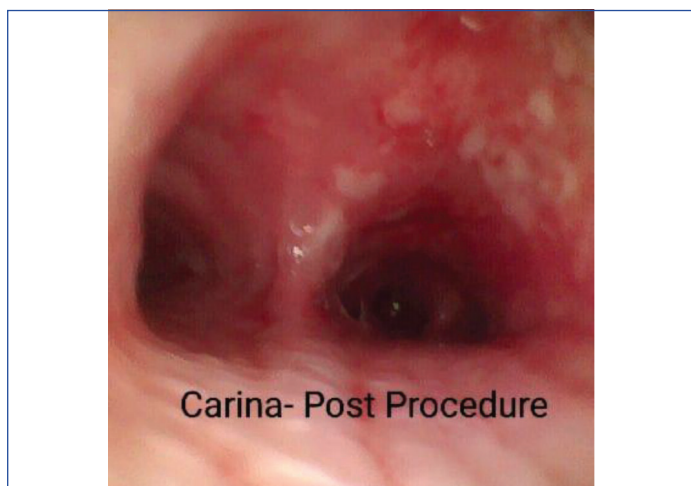

[Table/Fig-1]: Chest X-ray PA view showing foreign body in the right main stem bronchus.

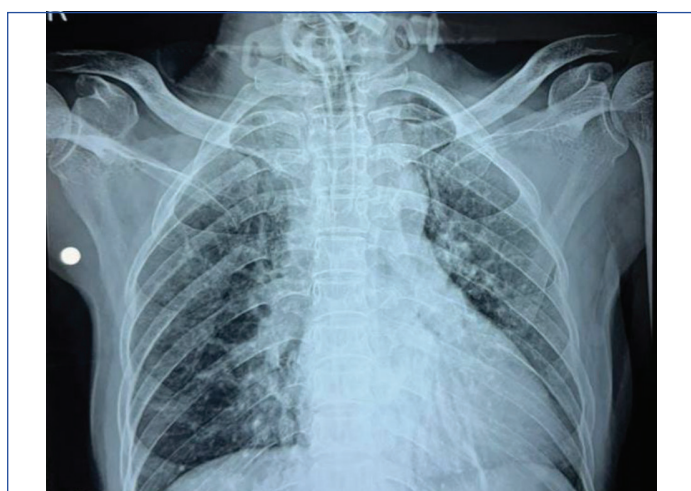


[Table/Fig-3]: Bronchoscopic view of a metallic foreign body that appears rusted.

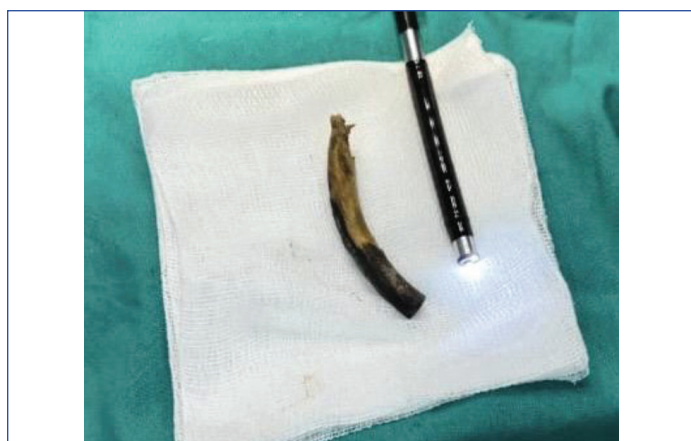The foreign body was removed using bronchoscopic extraction under general anaesthesia. A bronchoscopic image of the carina revealed a normal bifurcation with no foreign bodies or aberrant mucosa [Table/Fig-4]. Post-procedure, oxygen saturation on room air remained constant at 99%. She was observed for 48 hours and received humidified oxygen, chest physiotherapy, and broad-spectrum antibiotics. A postoperative chest radiograph revealed clearance of the right main bronchus [Table/Fig-5]. The extracted foreign body was confirmed to be a metallic tracheostomy tube [Table/Fig-6]. The patient was clinically stable after the treatment and was discharged on postoperative day 3 with instructions for chest physiotherapy and regular outpatient follow-up. She was asymptomatic at the 6-week follow-up visit, with no cough or dyspnoea recurrence.



[Table/Fig-4]: Bronchoscopic image showing normal carina after removal of foreign body from right main stem bronchus.



[Table/Fig-5]: Post-operative chest X-ray PA view showing absence of foreign body at right main stem bronchus, which was removed.



[Table/Fig-6]: Image showing the metallic rusted tracheostomy tube.

DISCUSSION

Tracheostomy is derived from two ancient Greek words: trachea (Greek tracheia) and stoma (Greek stoma), meaning "mouth." It refers to creating a semi-permanent or permanent aperture and inserting a tracheostomy tube to allow proper ventilation for the patient [1].

Tracheostomy is a life-saving treatment performed for various reasons, including airway blockage relief, tracheobronchial toileting, and secretion prevention. In most circumstances, it is used as a temporary remedy and is discontinued once the patient has recovered from the ailment for which it was prescribed [2].

The treatment is generally safe with reported mortality rate of less than 5%. However, two types of morbid complications may occur: early and late. Early problems include haemorrhage, pneumothorax, tracheostomy tube blockage, and infection at the stoma site. Common late problems include stomal granulations, stenosis, innominate vascular injury, and tracheo-oesophageal fistula [2].

The first report of a broken tracheostomy tube was made by HH Bosso in 1960, involving a silver-nickel alloy tube [1]. Fractures have been reported to be more common with metallic tracheostomy tubes [2-4]. In 1987, Gupta reported nine cases of cracked tracheostomy tubes that had migrated distally [5]. The most common fracture point in metallic tubes is at the intersection with the neck plate [3]. The most prevalent cause was saliva corrosion after continuous use. Displaced tube lodgements were most commonly found in the trachea and right main bronchus [6].

Anaesthetic management of a tracheobronchial foreign body is always a challenging situation, with the airway being shared by the surgeon and anaesthesiologist. Tracheobronchial obstruction caused by a detached portion of a fractured tracheostomy tube is a rare occurrence with dangerous implications [7]. [Table/Fig-7] shows a few cases reported in literature [8-11].

Author and year	Patient/site of lodgement	Duration retained	Management	Outcome
Fityani M et al., 2025 [8]	Adult; left main bronchus	Not clearly stated	Rigid bronchoscopy	Successful removal; complete recovery
Mrisho BE et al., 2019 [9]	Child; trachea (long-standing foreign body)	Many years (long-standing; exact duration not specified)	Removal via tracheostomy	Uneventful recovery
Meva'a Biouele RC et al., 2025 [10]	Adult; right bronchus	>1 year	Surgical/ bronchoscopic extraction	Full recovery
Sidam S et al., [11]	Adult; left main bronchus	Approx 20 years	Bronchoscopy retrieval	Clinical improvement; stable postoperative course

[Table/Fig-7]: Summary of a few previously documented examples in the literature [8-11].

Bronchoscopy is the gold standard for diagnosis and treatment. Rigid bronchoscopy is preferred for large or long-standing foreign bodies for better airway control and extraction. Flexible bronchoscopy can be diagnostic and therapeutic in certain cases, especially if the foreign body is small and accessible [8]. Bronchoscopic retrieval of the tracheostomy tube was successful in this case, providing immediate symptomatic relief.

CONCLUSION(S)

The case emphasises the importance of tracheostomy care, follow-up and radiological vigilance in preventing long-term morbidity.

It highlights the rarity of endobronchial foreign bodies in adults, especially in patients with a history of tracheostomy and unexplained respiratory problems. Prompt diagnosis and retrieval are crucial to avoid chronic consequences like recurrent infections, airway stenosis or permanent damage.

REFERENCES

- [1] Bassøe HH, Bøe Johs. Broken tracheotomy tube as a foreign body. *The Lancet*. 1960;275(7132):1006-07. Doi: 10.1016/s0140-6736(60)90890-4.
- [2] Antwi-Kusi A, Osei-Ampofo M, Mohammed DI, Addison W. Fractured tracheostomy tube – A case report of a 3-year old Ghanaian child. *Afr J Emerg Med*. 2012;2(3):114-16.
- [3] Pirochchai P, Lertchanaruengrit P, Vatanasapt P, Ratanaanekchai T, Thanaviratananich S. Fractured metallic tracheostomy tube in a child: A case report and review of the literature. *J Med Case Rep*. 2010;4:234. Doi: 10.1186/1752-1947-4-234. PMID: 20678211; PMCID: PMC2918633.
- [4] Krishnamurthy A, Vijayalakshmi R. Broken tracheostomy tube: A fractured mandate. *J Emerg Trauma Shock*. 2012;5(1):97.
- [5] Gupta SC, Ahluwalia H. Fractured tracheostomy tube: An overlooked foreign body. *J Laryngol Otol*. 1996;110(11):1069-71.
- [6] Gana PN, Takwoingi YM. Fractured tracheostomy tubes in the tracheobronchial tree of a child. *Int J Pediatr Otorhinolaryngol*. 2000;53(1):45-48.
- [7] Kendigelen P. The anaesthetic consideration of tracheobronchial foreign body aspiration in children. *J Thorac Dis*. 2016;8(12):3803-07.
- [8] Fityani M, Juma Y, Omari M, Tayyem I, Sweity R, Deeb M, et al. Fractured metallic tracheostomy tube as an unusual foreign body in the left main bronchus: A case report. *Clin Med Insights Case Rep*. 2025;18:11795476251346991.
- [9] Mrisho BE, Swai H, Ntunaguzi D, Massawe E, Saitabau Z, Abraham Z. An unusual long standing tracheal foreign body in a paediatric patient removed via tracheostome: A case report. *Indian Journal of Case Reports*. 2019;5:1-3. 10.32677/IJCR.2019.v05.i03.025.
- [10] Meva'a Biouele RC, Andjock Nkouo YC, Mossus Y, Soua Essi FL, Kuissu P, Mindja Eko D, et al. Unusual removal of a fractured tracheostomy tube retained in the right bronchus for more than one year: A case report. *J Sci Dis [Internet]*. 2025 May 19 [cited 2025 Dec. 9];2(2):74-77. Available from: <https://jsd-fmns-ueb.com/index.php/pub/article/view/36>.
- [11] Sidam S, Sahoo AK, Jibin CJ. Tracheostomy tube, an unusual foreign body in left main bronchus: A case report. *Indian Journal of Applied Research*. 2024;14(9):21-22.

PARTICULARS OF CONTRIBUTORS:

1. Junior Resident, Department of Radiodiagnosis, Datta Meghe Institute of Higher Education and Research, Wardha, Maharashtra, India.
2. Senior Resident, Department of Neurology, Sanjay Gandhi Postgraduate Institute of Medical Sciences (SGPI), Lucknow, Uttar Pradesh, India.
3. Professor and Head, Department of Radiodiagnosis, Datta Meghe Institute of Higher Education and Research, Wardha, Maharashtra, India.
4. Junior Resident, Department of Radiodiagnosis, Datta Meghe Institute of Higher Education and Research, Wardha, Maharashtra, India.

NAME, ADDRESS, E-MAIL ID OF THE CORRESPONDING AUTHOR:

Dr. Komal Rathod,
Junior Resident, Department of Radiodiagnosis, Jawaharlal Nehru Medical College, Sawangi, Wardha-442005, Maharashtra, India.
E-mail: rathodkomal9527@gmail.com

PLAGIARISM CHECKING METHODS: [Jain H et al.]

- Plagiarism X-checker: Nov 12, 2025
- Manual Googling: Jan 15, 2026
- iThenticate Software: Jan 17, 2026 (3%)

ETYMOLOGY: Author Origin

EMENDATIONS: 6

AUTHOR DECLARATION:

- Financial or Other Competing Interests: None
- Was informed consent obtained from the subjects involved in the study? Yes
- For any images presented appropriate consent has been obtained from the subjects. Yes

Date of Submission: **Aug 24, 2025**

Date of Peer Review: **Nov 18, 2025**

Date of Acceptance: **Jan 19, 2026**

Date of Publishing: **Jun 01, 2026**